

# The Expression of VEGF-A in Maxillary Mucosal Tissue of Mucormycosis Infection on Dental Extraction after Hyperbaric Oxygen Therapy

<sup>1</sup>Fanny Margaretha Laihad, <sup>2</sup>I Ketut Sudiana, <sup>3</sup>M. Guritno S, <sup>4</sup>Sumarno, <sup>5</sup>Sunarjo, <sup>6</sup>Retno Indrawati, <sup>7</sup>Theresia Indah Budhy,, <sup>8</sup>Noengki Prameswari, <sup>9</sup>Arya Brahmanta, <sup>10</sup>Eddy Hermanto, <sup>11</sup>Monika Elidasari,

<sup>1,8-11</sup> Faculty of Dentistry Hang Tuah University Surabaya

<sup>2,5</sup> Faculty of Medicine Airlangga University Surabaya

<sup>3</sup> Faculty of Medicine UPN Veteran University Jakarta

<sup>4</sup> Faculty of Medicine Brawijaya University Malang

<sup>6,7</sup> Faculty of Dentistry Airlangga University Surabaya

Email: [fanny.mlaihad@hangtuah.ac.id](mailto:fanny.mlaihad@hangtuah.ac.id)

DOI: 10.31364/SCIRJ/v7.i3.2019.P0319618

<http://dx.doi.org/10.31364/SCIRJ/v7.i3.2019.P0319618>

**Abstract: Objective:** Mucormycosis is a rare invasive fungal infection, but fatal when it occurs and triggered by tooth extraction, cause damage of the oral mucosa gingival tissue. The aim of this study is to analyze the expression of VEGF-A in maxillary mucosal tissue of mucormycosis infection on dental extraction after Hyperbaric Oxygen (HBO) therapy.

**Material and methods:** It was a true laboratory experimental study with post test only control group design, using 34 male marmots with mean age of 3-4 month and body weight 300-400 gram and were divided in 6 groups by random allocation : 1 control group, 1 group of dental extraction and 4 intervention group. Two group, first with injection of  $10^6$ CFU/ml *Rhizopus oryzae* strain CBS 110.17 0,3 ml, and then tooth extraction. The other two group, dental extraction first and then rhizopus oryzae injection. The four intervention group were divided with non HBO and HBO treatment of 2,4 ATA 3x30 minute, one session, for 5 days. The expression of VEGF-A was examined by immunochemistry.

**Results:** Mean and Standard deviation in Normal (K-1)  $0,37\pm 0,15$ ; Dental extraction (K-2)  $2,20\pm 0,47$ ; *Rhizopus oryzae* injection and dental extraction non HBO (K-3)  $3,65\pm 0,69$ ; *Rhizopus oryzae* injection and dental extraction with HBO (K4)  $8,50\pm 1,35$ ; Dental extraction and *Rhizopus oryzae* injection non HBO (K5)  $4,40\pm 0,79$ ; Dental extraction and *Rhizopus oryzae* injection with HBO (K6)  $9,48\pm 0,61$ .

**Conclusion:** Hyperbaric oxygen therapy 2,4 ATA, 3x30', one session for 5 days has been significantly proven to increase the expression of VEGF-A in macrophage of maxillary mucosal tissue which infected by mucormycosis on dental extraction 25,6 times (K-6) and 23 times (K-4) more higher than normal group.

**Keywords:** Expression of VEGF-A; Maxillary Mucosal; Mucormycosis; Hyperbaric oxygen.

## Introduction

Fungal infections, also called mycoses, are important causes of morbidity and mortality in humans. Some fungal infection are endemic, and these infection usually caused by fungi that are present in the environment and whose spores enter human. Other fungal infections are said to be opportunistic because the causative agents cause mild or no disease in healthy individuals but may infect and cause severe disease in immunodeficient persons. The human airway is continuously open to the non sterile environment where fungal spores have the potential to reach lung tissue and produce disease.<sup>1</sup> Mucormycosis is a rare opportunistic fungal infection which affects less than two people in a million.<sup>2</sup> However, it is a life-threatening infection and fatality rate can be as high as 50 to 100%.<sup>3</sup> Mucormycosis is one of the most rapidly progressing and lethal form of fungal infection in humans which usually

[www.scirj.org](http://www.scirj.org)

© 2019, Scientific Research Journal

<http://dx.doi.org/10.31364/SCIRJ/v7.i3.2019.P0319618>

begins in the nose and paranasal sinuses. This fungus invades the arteries, forms thrombi within the blood vessels that reduce blood supply and cause necrosis of hard and soft tissues.<sup>4</sup> Although rare, the common form of this opportunistic fungal infection is seen in the rhinomaxillary region.<sup>5</sup> Common fetures of rhinocerebral, pulmonary and disseminated diseases include blood vessel invasion, hemorrhagic, necrosis, thrombosis and a rapid fatal outcome.<sup>6</sup> Oral manifestation of these infections occur when the organism enter through an invasive portal such as a dental extraction.<sup>7</sup> The most impotant species in order of frequency is *Rhizopus arrhizus (oryzae)*.<sup>8</sup>

The use of hyperbaric oxygen as adjunctive treatment for Zygomycosis has been reported since 1970s and hyperbaric oxygen treatment is usually well tolerated and is associated with low risk of adverse events.<sup>9</sup> Hyperbaric oxygen therapy has been used as an adjunct to aggressive surgical debridement, amphotericin B therapy , control of any underlying predisposing conditions by aiding neovascularization and subsequent healing .<sup>5</sup> Hyperbaric oxygen therapy has also been used to treat mucormycosis.<sup>8</sup>

VEGF (Vascular endothelial growth factor), a glycoprotein, has attracted attention as a potential inducer of angiogenesis. It is detectable in periodontal tissues within endothelial cells, plasma cells, and macrophages and in junctional, sulcular, and gingival epithelium.<sup>10</sup> VEGF found in saliva plays an important role in wound healing in the oral mucosa.<sup>11</sup> VEGF-A is a member of 7 members of the VEGF family.<sup>12</sup> Brown LF study, reported that the over expression of VEGF-A occurs during the initial phase of wound healing.<sup>13</sup>

This study was conducted to analyze the expression of VEGF-A after therapy with hyperbaric oxygen in maxillary mucosal tissue of mucormycosis infection on tooth extraction.

## Material and Methode

Before this study was done, it has been preceded by two preliminary research processes in-vitro and in-vivo to observe the effect of hyperbaric oxygen on 10<sup>6</sup> *Rhizopus Oryzae* Strain CBS 110.17 (mucormycosis agent) and the healing effect of hyperbaric oxygen on experimental animal (marmots) wich made infected by mucormycosis on dental extraction.<sup>15</sup> This in-vitro study was to examine the effect of hyperbaric oxygen to the growth of mucormycosis agent *Rhizopus Oryzae* strain CBS 110.17 after fourteen times treatments with hyperbaric oxygen in macroscopic and microscopic aspects.<sup>14</sup> The result implicate that HBO have effect on *Rhizopus oryzae* Strain CBS 110.17.<sup>15</sup>

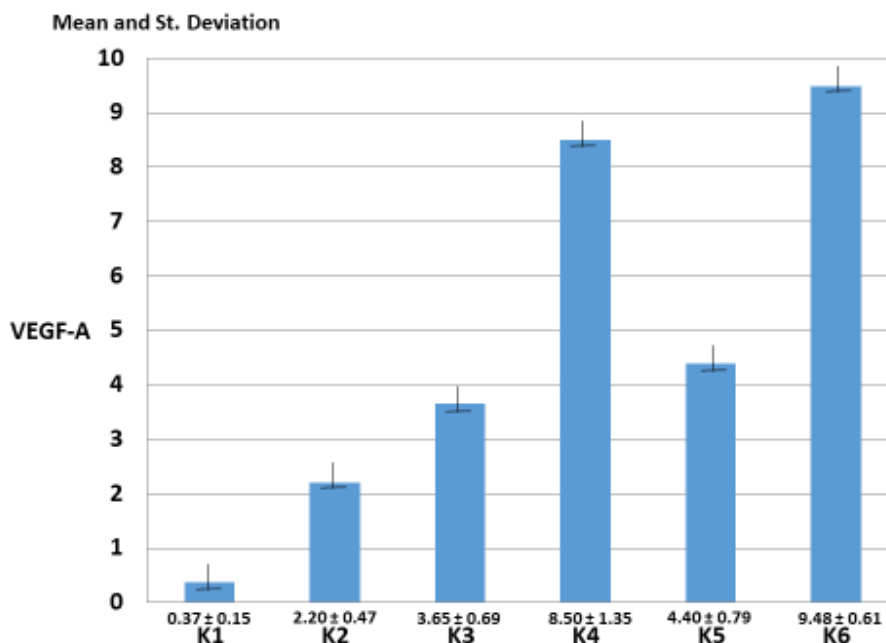
In in-vivo preliminary study, it was found that hyperbaric oxygen therapy had an effect on repair of damaged gingival mucous tissue due to mucormycosis infection both in maxillary and mandibular after extraction. On the lower jaw (mandibular), with tooth extraction first and then fungal injection, compared with maxilla , fungal injection first and on the third day , the tooth extract and there is a difference in tissue damage. The tissue damage in maxillae is worse than the mandible, but after being given HBO therapy, healing in the maxilla is better than the mandible.<sup>16</sup>

In the study of the expression of VEGF-A to the effect of Hyperbaric oxygen in mucormycosis infection in maxillary gingiva mucosa on dental extraction was a true laboratory experimental study with post test only group design. Thirty four (34) male marmots with mean age of 3-4 month and body weight 300-400 gram and were divided in 6 groups by random allocaton : 1 control group, 1 group of dental extraction and 4 intervention group. Two group, first with injection of 10<sup>6</sup>CFU/ml rhizopus oryzae strain CBS 110.17 0,3 ml ,after the third day, tooh extraction. The other two group, dental extraction first and then rhizopus oryzae injection . The four intervention group were divided with none HBO and HBO treatment of 2,4 ATA 3x30 minute, one session, for 5 days. The expression of VEGF-A was examined by immunochemistry.

## Results

**Table 1. Mean and Standard Deviation of VEGF-A Expression in all Group.**

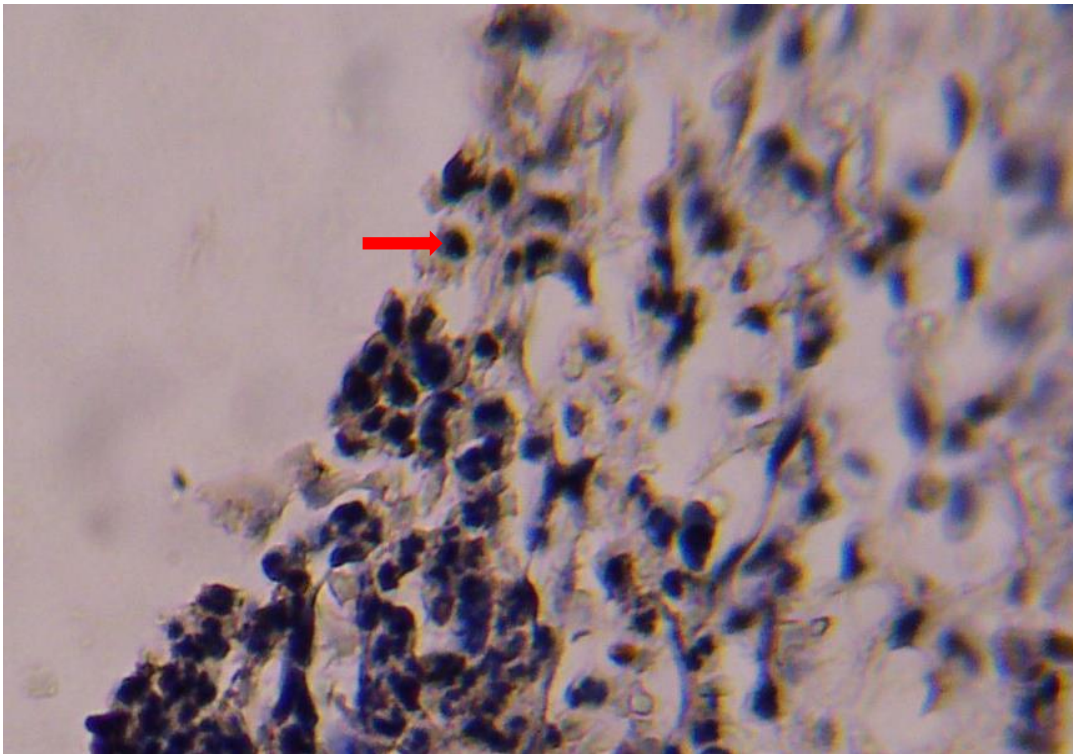
Variabel	Normal (n=6) K-1	Dental Extraction (n=5) K-2	<i>Rhizopus</i> Injection → Dental extraction + HBO (n=6) K-3	Dental extraction → <i>Rhizopus</i> Injection Non HBO (n=6) K-4	Dental extraction → <i>Rhizopus</i> Injection Non HBO (n=6) K-5	Dental extraction → <i>Rhizopus</i> Injection +HBO (n=5) K=6
VEGF-A	0,37±0,15	2,20±0,47	3,65±0,69	8,50±1,35	4,40±0,79	9,48±0,61



**Figure 1. Diagram of mean and standard deviation of VEGF-A expression on macrophage in all group**

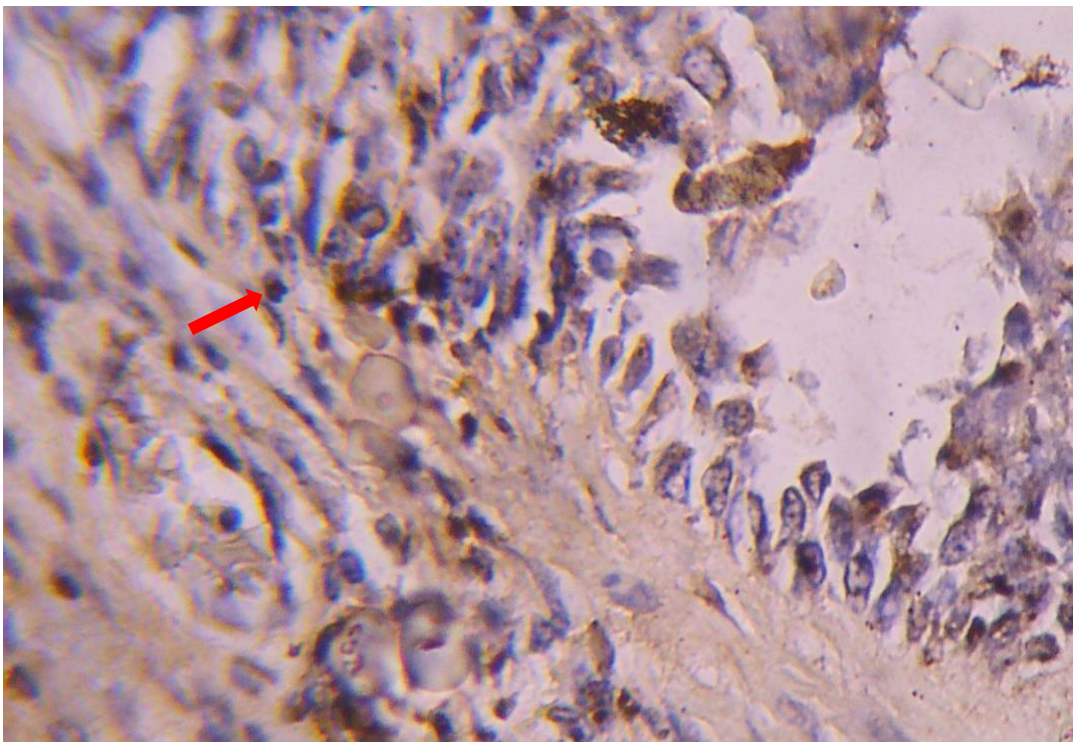
**Table 2. The comparative results of VEGF-A expression between K1 and the other group**

Variabel	K1 - K2	K1 - K3	K1 - K4	K1 - K5	K1 - K6
VEGF-A	5,9*	9,9 *	23*	11,9*	25,6*



**Figure 2. Microscopic images of expression results of VEGF-A in Group-5 (K-5) (Dental extraction → *Rhizopus* Injection Non HBO**

A brown macrophage cell appears (↔ ) to give a positive reaction to the anti VEGF-A monoclonal antibody on the periodontal tissue: Magnification 400 times.



**Figure 3. Microscopic images of VEGF-A expression results in Group-6 (K-6): the action of tooth removal → rhizopus injections and received HBO therapy.**

A brown macrophage cell appears (→) to give a positive reaction to the anti VEGF-A monoclonal antibody on the periodontal tissue: Magnification 400 times.

The above research data, all distributed normally with statistical test Kolmogorov-Smirnov Z one sample, then done parametric statistical test that is analysis on correlation, significance test and double comparison test between groups as in the next table below.

**Table 3. Result of normality test of research variable in each group.**

No	Variabel	Normal (n=6) K1	Dental extraction (n=5) K2	Rhizopus Injection → Dental extraction Non HBO (n=6) K3	Rhizopus Injection → Dental extraction + HBO (n=6) K4	Dental extraction → Rhizopus Injection Non HBO (n=6) K5	Dental extraction → Rhizopus Injection + HBO (n=5) K6
1	VEGF-A	0,83	0,76	0,95	0,98	0,94	0,96

**Table 4. Comparative Test Results in Groups K1, K2, K3, K4**

Variabel	Normal (K1)	Dental extraction (K2)	Rhizopus Injection → Dental extraction -OHB (K3)	Rhizopus Injection → Dental extraction + HBO (K4)	p Value
Hsp-72	0,37±0,15 <sup>a</sup>	2,20±0,47 <sup>b</sup>	3,65±0,69 <sup>b</sup>	8,50±1,35 <sup>c</sup>	<0,0001

Wilks' Lambda ; F = 24,278 ; value p < 0,0001

**Note :** different superscript letters show significant differences (p<0,05) using a double comparison test (a,b,c,d)

**Tabel 5. Comparative Test Results in Groups K1, K2, K5, K6**

Variabel	Normal (K1)	Dental extraction (K2)	Dental extraction → Rhizopus Injection -OHB (K5)	Dental extraction → Rhizopus Injection +OHB (K6)	p Value
Hsp-72	0,37±0,15 <sup>a</sup>	2,20±0,47 <sup>b</sup>	4,40±0,79 <sup>b</sup>	9,48±0,61 <sup>c</sup>	<0,0001

Wilks' Lambda ; F = 24,278 ; value p < 0,0001

**Note :** different superscript letters show significant differences (p<0,05) using a double comparison test (a,b,c,d)

**Discussion**

The aim of this study is to analyze the effect of Hyperbaric Oxygen (HBO) therapy on the expression of VEGF-A in maxillary mucosal tissue of mucormycosis infection on dental extraction. From the results of the above study, the exposed expression of VEGF-A increased after the HBO therapy was given. The samples were subjected to immunohistochemical analysis. In microscopic images of the expression results of VEGF-A, a brown macrophage cell appears to give a positive reaction to the anti VEGF-A

monoclonal antibody on the periodontal tissue with magnification 400 times. In detail from table-1 and table-2, the following results show that the expression of VEGF-A on K-6 ( group of tooth extraction, fungus injection with HBO) increases highest among other groups with a value of  $9,48 \pm 0,61$  (25,6 times to K-1 /normal), followed by K-4 (group of fungus injection, tooth removal with HBO) with  $8,50 \pm 1,35$  (23 times to normal). Group of tooth extraction, injection of the fungus without HBO (K-5) which is  $4,40 \pm 0,79$  (11,9 times to normal) and K-3 (fungus injection and tooth removal without HBO tooth extraction) with  $3,65 \pm 0,69$  (9,9 times to normal) and the smallest is K-2 (tooth extraction ) only  $2,20 \pm 0,47$  (5,9 times to normal ).

According to the theory, VEGF (*vascular endothelial growth factor*) acts as an angiogenesis factor. Angiogenesis occurred under pathological condition contributing to the degree of inflammation as a result the new blood vessels transport proinflammatory cells to the lesion and supply oxygen, nutrient to the inflamed tissue.<sup>17</sup> Vascular endothelial growth factor (VEGF) is a chemical signal produced by cells that stimulate new blood growth. This is part of a system that returns oxygen supply to the tissues if blood circulation is inadequate. The normal function of VEGF is to create new blood vessels during embryonic development, new blood vessels after injury and new blood vessels (collateral circulation) to cut off block vessels.<sup>18</sup> VEGF (Vascular endothelial growth factor), a glycoprotein, has attracted attention as a potential inducer of angiogenesis. It is detectable in periodontal tissues within endothelial cells, plasma cells, and macrophages and in junctional, sulcular, and gingival epithelium.<sup>10</sup> VEGF found in saliva plays an important role in wound healing in the oral mucosa.<sup>11</sup> Brown LF study, reported that the over expression of VEGF-A occurs during the initial phase of wound healing.<sup>13</sup> Numerous cytokines and growth factors are involved in the regulation of angiogenesis. The most potent agent that acts specifically on vascular endothelium is vascular endothelial growth factor (VEGF).<sup>17</sup> VEGF-A is a member of 7 members of the VEGF family.<sup>12</sup> VEGF-A is identified originally as a specialized mitogen for endothelial cells and the significance of VEGF in vascular development invivo studied through rats as experimental animals.<sup>19</sup> VEGF-A increases mucosal angiogenesis and stimulates leukocyte adhesion in vivo.<sup>20</sup> Hyperbaric oxygen therapy has been shown to increase the expression of VEGF on disability although 2 weeks after treatment ends 6 weeks after surgery.<sup>21</sup> Liu X.*et al* (2014) in research on spinal cord injuri given Hyperbaric oxygen therapy, found that the expression levels of VEGF increased in spinal cord injuri with HBO compared to group of spinal cord injuri without HBO.<sup>22</sup>

The results of this study illustrate that in each treatment groups, the expression of VEGF-A differs significantly (table-5) through the symbols of letters (a/b/c) which are most increased in K-6, then K-4 which also receives HBO therapy, followed by K-5 and K-3 without HBO therapy and K-2 , tooth extraction, the smallest. This study analyzed the expression of VEGF-A in the maxillary mucosal tissue damaged by mucormycosis infection on tooth extraction after HBO therapy in macrophages of periodontal tissue. Prapulla (2007) indicated that VEGF plays a key role in periodontal disease progression and can be considered a biomarker of periodontal disease progression.<sup>10</sup> Ramya and Kumar (2014) investigates the association between VEGF, Diabetes mellitus and periodontitis. The level of the expression of VEGF was higher in diabetics patients with periodontitis when compared to non diabetic patients with chronic periodontitis.<sup>17</sup>

In this study, the maxillary mucosa was made infected by a fungal infection and tooth extraction which would trigger an increase in VEGF-A expression. With HBO therapy, the expression of VEGF-A more increases according to the research of Fok *et al* (2006) and Liu *et al* (2014) and the same with what Brown LF (1988) studied and reported that the over expression of VEGF-A occurs during the initial phase of wound healing.<sup>13,21,22</sup> This happens as a result of the infection and then given HBO therapy which will trigger an increase of VEGF-A expression to immediately form new blood vessels in the injuri region.<sup>18</sup> In In the group that was given HBO or without HBO therapy, that have tooth extraction first and injected with fungus , the expression of VEGF-A was more higher than the group of injected fungus first and then removed teeth. This is due to the trauma that involves the blood vessels will make an increase in VEGF-A expression because VEGF-A is a chemical signal produced by cells that stimulate new blood growth.<sup>18</sup>

## Conclusion

Hyperbaric oxygen therapy 2,4 ATA 3x 30 minute, one session for 5 days has been significantly proven to increase the expression of VEGF-A in macrophage of maxillary mucosal tissue which infected by mucormycosis on dental extraction 25,6 times (K-6) and 23 times (K-4) more higher than normal group.

## References

1. Puebla, L.E.J. *Fungal infections in immunosuppressed Patients* (2012). Licensee In Tech.
2. Bouza E, Munoz P, Guinea J. *Mucormycosis : an emerging disease ?* Clin Microbiol Infect 2006 ;12:7-23
3. Goel S, Palskar S, Shetty VP, Bhushan A. *Rhinomaxillary mucormycosis with cerebral extention.* J Oral Maxillofac Pathol 2009;13(1):14-17
4. Leitner C, Hoffmann J, Zerfowski M, Reinert S, *Mucormycosis : necrotizing soft tissue lesion of the face.* J Oral Maxillofac Surg 2003;61:1354-8
5. Mohanty N, Misra S.R., Sahoo S.R., Mishra S., Vasudevan V., Kailasam S.. *Rhinomaxillary Mucormycosis masquerading as Chronic Osteomyelitis : A series of four rare cases with review literature.* J Indian Aca Oral Med Radiol 2012 ;24(4):315-323
6. Morace Giulia and Borghi Elisa. *Invasive Mold Infections : Virulence and Pathogenesis of Mucorales.* International Journal of Microbiology , volume 2012, Article ID 349278, 5 pages.
7. Fogarty C , Regennitter F, Viozzi CF. *Invasive fungal infection of the maxilla following dental extraction in a patient with chronic obstructive pulmonary disease.* J Can Dent Assoc 2006;72(@):149-5
8. Garlapatti K, Chavva S, Vaddeswarupu RM, Surampudi J. *Fulminant Mucomycosis Involving Paranasal sinuses : A rare case report.* Case Reports in Dentistry 2014, Volume 2014, article ID 465919, 4 pages
9. Tragiannidis A., Groll A.H., *Hyperbaric Oxygen Therapy and other adjunctive treatments for zygomycosis.* Clinical Microbiology and Infection, 15:82-86.doi:10.1111/j.1469-0691.2009.02986.x
10. Prapulla DV, et al. *Gingival crevicular fluid VEGF levels in Periodontal Health and Disease.* J Periodontol. 2007 Dec;78(12):2395.
11. Leung A., Keswani SG., Balaji S., Le L., Ghobril N., Lim F., Habli M., Jones HN., Crombleholme TM . *Salivary VEGF plays an essential role in oral mucosal wound healing.* Journal surgical research Feb 2012, volume 172, Issue 2, page 300.
12. Hoeben A., Landuyt B., Highley MS., Wildiers H., Van Oosterom AT., De Bruijn EA. *Vascular Endothelial Growth Factor and Angiogenesis.* Pharmacological Reviews December 2004 . Vol.56 no. 4 549-580.
13. Brown LF., Van De Water L., Harvey VS, Dvorak HF. *Fibrinogen influx and accumulation of cross-linked fibrin in healing wounds and in tumour stroma.* Am J Pathol 1988;130:455-65
14. Barratt DM ,Meter K.V, Asmar P., Nolan T., Trahan C, Covarrubias LG, Metzinger SE.(2001). *Hyperbaric oxygen as an adjunct in zygomycosis : randomized controlled trial in a murine model.* Antimicrob agents chemother . december;45(12):3601-3602.
15. Fanny M. , I Ketut Sudiana, Guritno S. *The effect of hyperbaric oxygen to the growth of Mucormycosis agent rhizopus oryzae strain CBS 110.17 (an in-vitro preliminary study).* Scholarly Journal of Medicine 2017 Vol. 5(1),pp 14-20, April
16. Laihad, Fanny Margaretha. *Mucormycosis in the Oral Cavity with Hyperbaric Oxygen Therapy.* Lambert Academic Publishing. 2017 ISBN: 978-3-330-33226-3. ICS Morebooks, Balti, Republic of Moldova. p.69-74
17. Ramya and Kumar S. *Expression of VEGF in Periodontal tissues of type II Diabetes Mellitus patients with Chronic Periodontitis – an immunohistochemical study.* J Clin Diagn Res.2014 Aug;8(8):ZC01-ZC03.
18. Khilman HP. *VEGF Pathway.* Farmakologi Unsoed by farmol Dec. 2012
19. Kano MR., Morishita Y., Iwata C., Iwasaka S., Watabe T., Ouchi Y., Miyazono K., Miyazawa K. *VEGF-A and FGF-2 synergistically promote neoangiogenesis through enhancement of endogenous PDGF-B-PDGFR $\beta$  signaling.* Journal of cell Science 2005,118,3759-3768.
20. Scaldaferrri F., Vetrano S., Sans M., Arena V., Straface G., Stigliano E., Repici A., Sturm A., Malesci A., Panes J., Yla-Herttuala S., Fiocchi C., Danese S. *VEGF-A links angiogenesis and inflammation in inflammatory bowel disease pathogenesis.* Gastroenterology, Feb 2009,136(2):585-95
21. Fok TCO., Jan A., Peel SAF., Evans AW.,Clokie CML., Sandor GKB. *Hyperbaric oxygen results in increase vascular endothelial growth factor (VEGF) protein expression in rabbit calvarial critical-sized defects.* Oral surgery, oral medicine,oral pathology, oral radiology and endodontology April 2006, volume 105, issue 4, pages 417-422

22. Liu X., Zhou Y., Wang Z., yang j., Gao C., Su Q. *Effect of VEGF and CX43 on the promotion of neurological recovery by hyperbaic oxygen treatment in spinal cord –injured rats*. The spine journal January 1, 2014, volume 14, issue 1 pages 119-127